



Varicella Zoster Virus Aseptic Meningitis: A Misleading Clinical And Laboratory Presentation: Three Case Reports

Diana Khedr* Shaimaa H Soliman and Sulaiman Alkhashan

Department of Neurology, Farwanya Hospital, Kuwait

*Correspondence

Diana Khedr

Department of Neurology, Kasralainy Hospital, Cairo University, Egypt

E-mail: ianamahmoud46@yahoo.com

• Publication Date: 19 Oct 2022

Keywords

Varicella zoster virus, Cerebrospinal fluid, IIH, Aseptic meningitis, Three cases report.

Copyright

© 2022 Authors. This is an open- access article distributed under the terms of the Creative Commons Attribution 4.0 International license.

Abstract

Background: A septic meningitis caused by varicella zoster virus (VZV) reactivation was less described in the literature, Varicella-zoster virus is a neurotropic virus that remain dormant in dorsal root ganglion after primary infection, usually manifested as chickenpox which gets reactivated in immunocompromized state presented usually with vesicular rash complicated with multi-organ affection such as central nervous system. Rarely this characteristic skin rash can be absent initially requiring high clinical suspicion for diagnosis. When no skin lesions are present, a high clinical suspicion is required to reach the diagnosis. In this report we described three clinical of varicella-zoster virus reactivation presented in atypical way in terms of clinical presentation and cerebrospinal fluid analysis.

Case presentation: Three patients otherwise healthy were admitted to the hospital with a chief complaint of headache, nausea, vomiting and symptoms suggestive of increased intracranial pressure (IIH). Resembling IIH but due to acute presentation and positive meningeal signs this was unlikely. The clinical examination did not show any neurological deficits or rash except lately in the first case. Lumbar puncture unexpectedly showed high opening pressure with markedly elevated CSF total and high total cell count with lymphocytic predominance which was misleading raising suspicion of tuberculous meningitis. Further CSF analysis, including polymerase chain reaction (PCR) and detection of intrathecal synthesis of antibodies, showed a VZV infection. Clinical follow-up examinations later on proved successful antiviral treatment.

Conclusion: In conclusion, absence of typical vesicular rash of varicella zoster initially as well as high opening CSF pressure with high CSF protein even young and previously healthy patients should not rule out consideration of varicella zoster meningitis.

Introduction

Infections with neurotropic herpes viruses (herpes simplex type 1 and 2, varicella zoster virus (VZV)) are frequent in humans. These viruses persist within cranial nerves, dorsal roots, and autonomic ganglia causing latent infections with the ability of reactivation [1]. Reactivation of VZV shows mainly a herpes zoster presenting with rash and pain affecting the entire dermatome and less frequently a zoster sine herpete [2–3]. VZV infection of the central nervous system (CNS) such as encephalitis, meningitis, myelitis, or angitis occurs less frequently but is feared because of the numerous unfavourable outcomes [1,3,4]. Usually CNS infection with VZV comes along with dermal affection but can rarely develop without rash [1,3,5]. Acute infection or VZV reactivation affects predominantly older individuals and/or immunocompromised patients [1–3]. CNS infection with VZV in young healthy adults is rare and is unexpected and only very few cases have been described

so far [5–7]. Here, we describe 3 cases of previously healthy young men with VZV meningitis who had only minimal symptoms.

Cases Presentation

First Case

A 41 -year-old male patient, previously healthy with no significant medical or surgical, presented to our emergency department with acute onset of severe headache, photophobia, phonophobia and once vomiting. On examination, He had also severe neck pain with positive meningeal signs otherwise normal neurological examination with normal fundus examination. Initial computed tomography on brain and angiography to rule out subarachnoid hemorrhage and dissection were unremarkable. A lumbar puncture showed high opening pressure of 26 cm H₂O, high total cell count of 500 cell / mm³ with 97% lymphocytic predominance, high proteins of 1434 mg/dl, negative TB PCR, negative culture

Citation: Khedr D, Shaimaa HS, Alkhashan S Varicella Zoster Virus Aseptic Meningitis: A Misleading Clinical And Laboratory Presentation: Three Case Reports . Arch Microbiol Infect Dis. 2022; 1(1):1-3.

and sensitivity and positive virology PCR for VZV (Table 1). Patient showed marked improvement of headache after lumbar puncture. Brain magnetic resonance imaging (MRI) with IV gadolinium was essentially normal. Human immunodeficiency antibodies (HIV) were negative, VZV aseptic meningitis diagnosis was considered, antiviral therapy with intravenous acyclovir 10 mg/kg/dose every 8 hrs for 14 days was given with marked improvement Interestingly on third day of antiviral therapy VZV eruption rash started to appear on his chest following dermatomal distribution.

Second Case

A 40-year-old male previously healthy, presented to our emergency department with acute onset of severe headache and photophobia associated with low grade fever with no skin rash. He had otherwise normal neurological examination with normal fundus examination with no meningeal signs. Initial computed tomography on brain and angiography to rule out subarachnoid hemorrhage and dissection were unremarkable. A lumbar puncture showed high opening pressure of 22 cm H₂O, revealed high total cell count of 152 cell / mm³ with 60% lymphocytic predominance, high proteins of 1792 mg/dl, negative TB PCR, negative culture and sensitivity, and positive virology PCR for VZV (Table 1). Patient showed marked improvement of headache and photophobia after lumbar puncture. Brain magnetic resonance imaging (MRI) with IV gadolinium was essentially normal. Human immunodeficiency antibodies (HIV) were negative, VZV aseptic meningitis diagnosis was considered, antiviral therapy with intravenous acyclovir 10 mg/kg/dose every 8 hrs for 14 days was given with marked improvement back to his baseline status before discharge.

Third Case

A 29 yrs old male patient previously healthy, relatively obese with BMI of 35. He presented to our emergency department by five days history of low grade fever followed by sub-acute onset of severe headache of increased intracranial pressure character associated with nausea, vomiting, photophobia and increased on leaning forward. Few days later he started to have horizontal binocular diplopia. By examination, he had evident bilateral

esotropia with positive cover uncover test suggesting bilateral six nerve palsy (false localizing sign). Fundus examination showed grade 2 bilateral papilledema. There were no meningeal signs but he had severe agonizing neck pain, otherwise normal neurological examination. MRI brain showed picture suggestive of idiopathic intracranial hypertension (IIH) with flattening of globe bilateral and empty sella turcica (Figure 1). MRV was normal with no sinus thrombosis or stenosis. Lumbar puncture showed very high opening pressure above 40 cm H₂O suggesting initial diagnosis of IIH which was supported by MRI brain picture but other CSF parameters were atypical which showed high cell count of 75 cells /mm³ with lymphocytic predominance of 90%, very high protein of 1235 mg /l and positive VZV PCR. HIV Abs were negative, other workup to rule out other secondary causes associated with IIH including vasculitic work up (APL, SLE, sarcoidosis), hormonal profile were done and all were normal

Finally, A diagnosis of VZV aseptic meningitis complicated or coexisting with IIH picture was considered, antiviral therapy with intravenous acyclovir 10 mg/kg/dose every 8 hrs for 14 days was given with acetazolamide 500 mg TDS to control high CSF pressure with marked improvement of his symptoms before discharge.

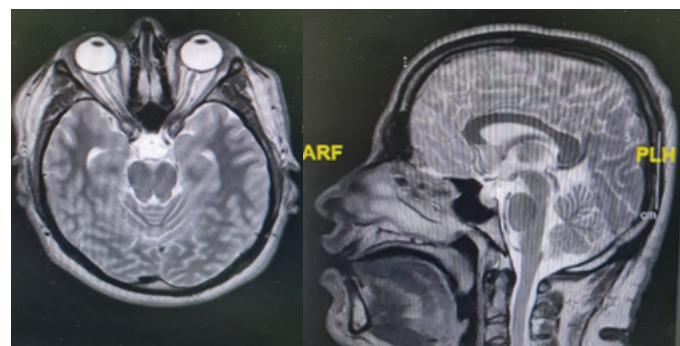


Figure 1. MRI brain of the third case suggestive of IIH

Figure 1. Summary of CSF parameters in the three cases

CSF parameters	First case	Second case	Third case	Ref. values
Opening pressure (cm H ₂ O)	26	22	Very high (above 40)	18-20
Color, opacity	Colorless, turbid	Colorless, slightly turbid	Colorless, turbid	Colorless, clear
Cell count/ mm ³	500	152	75	0-5 /mm ³
Differential count	97% lymphocytes	60%	90%	
Proteins level (mg/l)	1434	1792	1235	150-450
Glucose level (mmol/l)	2.3	2.5	2.3	(2.2-3.9)
LDH (unit/l)	19	23	10	0-40
CSF VZV DNA PCR	Positive by real time	Positive by real time	Positive by real time	Negative
Extensive CSF virology PCR (HSV,CMV, EPV, Enteroviruses)	Negative	Negative	Negative	Negative
Culture and sensitivity	Negative	Negative	Negative	Negative

Discussion

Reactivated VZV can cause wide varieties of neurologic disease [2,3]. The discovery of PCR increases the detection rate in diagnosis of viral meningitis due to varicella-zoster virus (VZV) [11]. Several studies conducted in patients with herpes zoster have demonstrated that subclinical meningeal irritation can occur in 40–50% of cases. [12,13], but a careful review of the literature showed that VZV-related neurologic disease can occur without the classic herpes zoster exanthema, even in immunocompetent patients as described lately by (Susan et al., 2022) [8-10]. The present cases demonstrate the same atypical phenomenon with the initial CSF findings with high lymphocytic pleocytosis and elevated total CSF protein initially misleadingly suggested CNS tuberculosis. Interestingly, further CSF examinations detected a VZV infection, but in the third case there were increased intracranial pressure as a predominant clinical feature. The mechanism behind this increase remains poorly understood. However, this can be explained by one of the postulated theories according to (Ibrahim et al., 2015) where superimposed infection of baseline subclinical pseudotumor cerebri or caused primarily by the VZV meningitis [14-16]. Further explanation suggested the post-infectious allergic response to the causative virus and diffuse brain swelling [16]. The high opening pressure in our patient compared to previous reported cases may favor the first theory – subclinical pseudo-tumor cerebri with super-added infection. However, the dramatic response to antiviral medication suggests that aseptic meningitis was the direct cause of her symptoms [10-12]. All patients received acyclovir intravenously for 1–2 weeks resulting in full recovery, suggesting that VZV meningitis tends to be of mild symptoms, good response to treatment and benign prognosis [17-19]. The difficulty in meningitis diagnosis is to distinguish whether it's a viral or bacterial etiology, because this is crucial for treatment decisions. The treatment threshold is usually set low in clinical work, so that antibiotics, even anti-tuberculosis treatment, are often prescribed in cases of doubt [18-20].

Conclusion

We report here three cases of atypical VZV aseptic meningitis with clinical presentation that varies from very reassuring to atypical IIH presentation and also with misleading laboratory results which may suggest tuberculous meningitis early before PCR virology results. In conclusion, we highlight the importance of considering VZV as a possible cause for meningitis even in previously healthy young patients and the recommended diagnostic lumbar puncture. Detailed CSF diagnostic procedures including PCR and detection of intrathecal synthesis of antiviral antibodies (especially for VZV and HSV) should be considered even though CSF cell count and total protein seem to indicate a bacterial infection.

Informed consent

Written informed consent was obtained for all cases

Conflict of interest

On behalf of all authors, the corresponding author states that there is no conflict of interest.

Funding sources

No fund was needed for this study

Author contribution

DK and SH responsible for data collection, analysis, interpretation of results and drafted the article. SE revised and approved the version to be published

References

- Eshleman E, Shahzad A, Cohrs RJ. Varicella zoster virus latency. *Future Virol.* 2011;6(3):341–55
- Gilden DH, Kleinschmidt-DeMasters BK, LaGuardia JJ, Mahalingam R, Cohrs RJ. Neurologic complications of the reactivation of varicella-zoster virus. *N Engl J Med.* 2000;342(9):635–645.
- Gnann JW. Varicella-zoster virus, atypical presentations and unusual complications. *J Infect Dis.* 2002;86:S91–98.
- Mantero V, De Toni Franceschini L, Lillia N, et al. Varicella-zoster meningo-encephaloradiculoneuropathy in an immunocompetent young woman. *J Clin Virol.* 2013;57(4):361–62.
- Gómez-Torres A, Medinilla Vallejo A, Abrante Jiménez A, Esteban Ortega F. Ramsay-Hunt syndrome presenting laryngeal paralysis. *Acta Otorrinolaringológica Española.* 2013;64(1):72–74.
- Haargaard B, Lund-Andersen H, Milea D. Central nervous system involvement after herpes zoster ophthalmicus. *Acta Ophthalmol.* 2008;86(7):806–9.
- Karmon Y, Gadoth N. Delayed oculomotor nerve palsy after bilateral cervical zoster in an immunocompetent patient. *Neurology.* 2005;65(1):170.
- Pasedag T, Weissenborn K, Wurster U, Ganzenmueller T, Stangel M, Skripuletz T. Varicella Zoster Virus Meningitis in a Young Immunocompetent Adult without Rash: A Misleading Clinical Presentation. *Case Rep Neurol Med.* 2014;2014:686218.
- Terborg C, Förster G, Sliwka U. Unusual manifestation of zoster sine herpete as unilateral caudal cranial nerve syndrome. *Der Nervenarzt.* 2001;72(12):955–57.
- Maigues Llacer JM, Pujol Fariols R, Pérez Sáenz JL, Fernández Viladrich P. Meningitis caused by varicella-zoster virus and ophthalmic trigeminal neuralgia without skin lesions in an immunocompetent woman. *Med Clin (Barc).* 1998;111(6):238–39.
- Franzen-Röhl E, Tiveljung-Lindell A, Grillner L, Aurelius E. Increased detection rate in diagnosis of herpes simplex virus type 2 meningitis by real-time PCR using cerebrospinal fluid samples. *J Clin Microbiol.* 2007;45(8):2516–20.
- Robillard RB, Hilsinger RL Jr, Adour KK. Ramsay Hunt facial paralysis: clinical analyses of 185 patients. *Otolaryngol Head Neck Surg.* 1986;95(3 Pt 1):292–97.
- Lee DH, Chae SY, Park YS, Yeo SW. Prognostic value of electroneurography in Bell's palsy and Ramsay-Hunt's syndrome. *Clin Otolaryngol.* 2006;31(2):144–48
- Ibrahim W, Elzouki AN, Husain A, Osman L. Varicella Zoster Aseptic Meningitis: Report of an Atypical Case and Literature Review. *Am J Case Rep.* 2015;16:594–597.
- Echevarría JM, Casas I, Tenorio A, et al. Detection of varicella-zoster virus-specific DNA sequences in cerebrospinal fluid from patients with acute aseptic meningitis and no cutaneous lesions. *J Med Virol.* 1994;43(4): 331–35.
- Lo S, Phillips DI, Peters JR, et al. Papilloedema and cranial nerve palsies complicating apparent benign aseptic meningitis. *J R Soc Med.* 1991;84(4):201–2.
- Zandian A, Osiro S, Hudson R et al. The neurologist's dilemma: a comprehensive clinical review of Bell's palsy, with emphasis on current management trends. *Med Sci Monit.* 2014;20:83–90.
- Aviel A, Ostfeld E, Burstein R, et al. Peripheral blood T and B lymphocyte subpopulations in Bell's palsy. *Ann Otol Rhinol Laryngol.* 1983;92:187–91.
- Greco A, Gallo A, Fusconi M et al. Bell's palsy and autoimmunity. *Autoimmun Rev.* 2012;12:323–28.
- Chaco J. Subclinical peripheral nerve involvement in unilateral Bell's palsy. *Am J Phys Med.* 1973;52:195–97.